



# Morphological Changes in the Atlantic Bottlenose Dolphin (*Tursiops truncatus*) Adrenal Gland Associated with Chronic Stress

L. S. Clark, D. F. Cowan<sup>\*,†</sup> and D. C. Pfeiffer

University of Alaska Anchorage, Department of Biological Sciences, 3211 Providence Drive, Anchorage, AK 99508, \*Texas Marine Mammal Stranding Network, 4700 Avenue U, Bldg 303, Galveston, TX, 77551-5926, and <sup>†</sup>The University of Texas Medical Branch, Department of Pathology, Galveston, TX, 77555-0555, USA

## Summary

Beach-stranded Atlantic bottlenose dolphins ( $n = 68$ ) were categorized as either “acutely stressed” (if they died from net entanglement, boat strike, or acute infection; 31 animals) or “chronically stressed” (if they suffered from or died as a result of long-term disease or debilitating injury; 37 animals). No significant differences in mass between the right and left adrenal glands were found within each category. However, the average gland mass (AGM), based on the right and left glands together, was 5.2 g for acutely stressed animals and 11.01 g for chronically stressed animals ( $P < 0.001$ ). Significant differences were also found, in terms of the ratio of cross-sectional areas of the cortex to medulla, between acutely stressed (ratio 1.22) and chronically stressed (ratio 1.63) animals ( $P = 0.027$ ). Adrenal glands of acutely stressed animals consisted of 48% cortex, 41% medulla, and 11% other tissue elements (connective tissue, blood vessels and gland capsule), whereas the corresponding figures for chronically stressed animals were 53%, 36%, and 11%. The mean estimated mass values for cortex, medulla and other tissue were, for acutely stressed animals, 2.36, 1.9, and 0.54, respectively, whereas for chronically stressed animals the corresponding figures were 6.06, 4.04, and 1.29 ( $P < 0.001$  for each of the three comparisons). Overstaining with haematoxylin (HEM) and immunohistochemical labelling (IHC) of the enzyme phenylethanolamine *N*-methyl transferase (which converts norepinephrine to epinephrine) were used to determine the percentage of epinephrine-producing cells in relation to the overall cross-sectional area of the adrenal gland. The percentage values in acutely as compared with chronically stressed dolphins were 6.7% and 15.93%, respectively ( $P = 0.021$ ). The results therefore suggest that in bottlenose dolphins chronic stress results in increases in (1) adrenal mass, (2) cortex to medulla ratio, and (3) epinephrine-producing cells within the medulla, giving rise to an increase in the thickness of the medullary band.

© 2006 Elsevier Ltd. All rights reserved.

**Keywords:** adrenal gland; bottlenose dolphin; cetacean; epinephrine; medullary band; stress (acute and chronic); *Tursiops truncatus*

## Introduction

The activation of a physiological stress response is often the only way in which mammals survive stressful events. One of the initial phases of a stress response is the activation of the HPA-axis (hypothalamus, pituitary and adrenal gland). This axis stimulates the production or release (or both) of hormones that mediate a stress response. Adrenal gland hormones, including

glucocorticoids, mineralocorticoids and catecholamines (norepinephrine and epinephrine), are necessary for an adequate stress response. Catecholamines play a particularly important role in the stress response by causing hyperglycaemia and increasing heart rate and blood pressure (Guyton and Hall, 2000; Randall *et al.*, 2002).

In extreme or prolonged stressful situations, for example those associated with predation attempts or separation from social groups, animals may be adversely affected by stress responses. Cowan (2000)

Correspondence to: L.S. Clark (e-mail: lance.clark@uaa.alaska.edu).

observed that marine mammals may exhibit an exaggerated stress response that causes deterioration or even death. Thus, in all stranded Atlantic bottlenose dolphins (*Tursiops truncatus*) examined by the Texas Marine Mammal Stranding Network, pathological changes attributable to acute or chronic catecholamine injury were noted in various tissues or organs (Turnbull and Cowan, 1998). Diseases such as capture myopathy (Spraker, 1993), stress cardiomyopathy (Cebelin and Hirsch, 1980), and contraction band necrosis (Turnbull and Cowan, 1998) may cause rapid death in mammals exposed to extremely stressful events, such as capture, violent assault, or beach stranding. While this holds true for mammals in general, it would seem to be particularly pronounced in cetaceans, in which the effects of catecholamines may impede attempts at rehabilitation. Indeed, catecholamine-induced injury may result in failure to survive stranding itself, let alone rehabilitation.

Research on the effects of chronic stress resulting from long-term disease on the cetacean adrenal gland is limited. Kuiken *et al.* (1993) associated chronic disease with adrenocortical hyperplasia in the harbour porpoise (*Phocoena phocoena*) and Lair *et al.* (1997) suggested that disease-related stress might account for cortical enlargement in stranded beluga whales (*Delphinapterus leucas*). Similarly, the effects of chronic stress resulting from long-term disease have been studied extensively in a variety of other mammals (Al-Lami and Farman, 1974; Sakellaris and Vernikos-Danellis, 1975; Anderson and Capen, 1978; Junqueira *et al.*, 1998).

The purpose of the present study was to examine the effects of both acute and chronic stress on the adrenal gland (particularly the medulla) of the Atlantic bottlenose dolphin, one of the most commonly stranded cetaceans.

## Materials and Methods

### *Animals and Samples*

All dolphins were collected between December 1989 and June 2003 from the northwestern Gulf of Mexico by the Texas Marine Mammal Stranding Network. These animals were either (1) beach-stranded alive, dying shortly afterwards, (2) washed on to the beach after death, (3) accidentally net captured and killed, or (4) humanely destroyed (or died) during rehabilitation. The collection area ranged from Cameron County at the Texas/Mexico border to Cameron Parish in Louisiana (i.e., the entire Texas Gulf Coast and part of Western Louisiana).

No animals included in this study showed signs of autolysis or decomposition at necropsy, which was per-

formed at Texas A & M University Galveston and included systematic sampling and examination of almost all major organs and tissues. A decision as to the cause of death was made after thorough examination by a pathologist (D.F.C.). As part of the sampling procedure, the left and right adrenal glands were removed from each animal and weighed on an electronic platform scale (model 4800P; Sartorius, Goettingen, Germany) to the nearest 0.01 g. A section *ca* 0.5 cm wide was then cut perpendicularly to the long axis from the middle of each gland and fixed in 10% neutral buffered formalin for several days at room temperature.

The animals in the study were divided into two categories, namely acutely stressed or chronically stressed. Those in the former category consisted of animals that had died rapidly as a result of boat strike, net entanglement, intraspecific aggression, or acute bacterial or viral infection. The adrenals of such animals, already described by Clark *et al.* (2005), would not have had time to develop significant cellular or structural changes. Accordingly, they were used as "normal" (control) glands for comparison with adrenals from chronically stressed animals, i.e., those with long-term diseases (e.g., hepatitis, pneumonia, degenerative arthritis) that would have been given sufficient time for the development of adrenal changes.

Sixty-eight bottlenose dolphins were examined. Of these, 31 animals were deemed acutely stressed and 37 animals were deemed chronically stressed. The former group consisted of 17 males (12 immature and five mature) and 14 females (13 immature and one mature), while the chronically stressed group consisted of 18 males (eight immature and 10 mature) and 19 females (four immature and 15 mature).

Sexual maturity was determined by gross and histological examination of the gonads for evidence of spermatozoa production in males and ovarian follicular development in females. Age was determined by counting growth layer groups in the dentine of teeth (Myrick *et al.*, 1983; Hohn *et al.*, 1989; Turner, 1998).

### *General Sectioning and Staining of Adrenal Tissue*

After fixation, adrenal tissue samples were embedded in paraffin wax and sections (5–8  $\mu$ m) were cut and mounted on glass slides. Three identical sets of slides (three slides of each gland per set) were prepared for various staining techniques. Slides of the first set were stained with either haematoxylin and eosin (HE) or haematoxylin, phloxine, and saffron (HPS). For each gland (right and left), HE or HPS sections were examined in triplicate with those slides being used for cross-sectional analysis of cortex to medulla ratios. The remaining two sets of sections were used for specific staining methods (see below).

### Histochemical Staining

The medullary band, a region within *T. truncatus* adrenal medulla in which epinephrine-producing cells are concentrated (Clark *et al.*, 2005), was identified by over-staining with Mayer's haematoxylin with Lillie's modification (HEM) for 15 min (typical haematoxylin staining time being 3–5 min). All counterstains were omitted. Confirmation that epinephrine-producing cells were restricted to the medullary band was obtained by the immunohistochemical (IHC) labelling of a subset of slides with a commercially available polyclonal antibody (Chemicon International, Temecula, CA, USA) raised against phenylethanolamine *N*-methyl transferase (PNMT), the enzyme that converts norepinephrine to epinephrine. The primary antibody (PNMT) was diluted 1 in 1000, as recommended by the manufacturer. IHC labelling was performed with the three-step avidin-biotin technique (Warnke and Levy, 1980) and proved to be effective with various bottlenose dolphin tissues, including adrenal glands (Kumar and Cowan, 1994; Cowan and Gatalica, 2002; Clark *et al.*, 2005). Quantitative measurements of medullary band staining (described below) were made to investigate possible differences between acutely and chronically stressed groups. Controls for immunolabelling included omission of primary antibody, omission of secondary antibody, and omission of the streptavidin conjugate.

### Morphometric Measurements

These were made on all HE or HPS slides by an established point-counting technique, to determine the ratio of the cross-sectional area of the cortex to that of the medulla (Weibel, 1963; Dunnill, 1968; Abdalla and Ali, 1989). A 25-point hexagonal lattice reticle was used for this analysis as described by Hennig (1958) and Weibel (1963). Cross-sectional measurements were performed in triplicate per adrenal gland (right and left), the average measurements being used for quantitative analysis. Given that the ratio of cortex to medulla remains constant over the length of the adrenal gland in *T. truncatus* (Clark *et al.*, 2005), it was possible to use the tissue sections, collected from the middle of each gland, to estimate cortical, medullary and "other" masses ("other" consisting of connective tissue, blood vessels, and the gland capsule). Estimates of cortical, medullary and "other" masses were derived by multiplying the percentage of the cross-sectional area of each of these three regions by the adrenal gland mass.

Digital images and imaging software were used to measure the percentage of IHC ( $n = 5$  acute and 7 chronic cases) and haematoxylin ( $n = 8$  acute and 6 chronic cases) staining of epinephrine-producing cells as compared with the overall cross-sectional area of

the adrenal gland. All measurements were performed in triplicate and examined by means of a Nikon Eclipse E400 compound microscope (Nikon Corporation, Tokyo, Japan) with a Q-Imaging Micropublisher digital camera (Q-Imaging, Burnaby, BC, Canada) and Meta Vue (version 6.0r5) Digital Imaging Software (Molecular Devices Corporation, Sunnyvale, CA, USA).

### Statistical Analysis

Nonparametric one-sample Kolmogorov–Smirnov tests were run before any analyses to check for normality. Paired *t*-tests were used to examine differences between gland mass and cortex to medulla ratios of the left and right adrenal glands. Analysis of covariance (ANCOVA) tests were used to compare sexes, stages of sexual maturity, and type of stress (acute *vs* chronic) in terms of average adrenal gland mass and average cortex to medulla ratio. To correct for the effects of age on adrenal gland mass, total body length (cm) was used as a covariate. Total body mass was not included in any analysis. Emaciation is a common problem with stranded cetaceans, making body mass a poor indicator of age or maturity status.

ANCOVA tests were again performed to make the same comparisons as those listed above, but this time in terms of percentage of IHC labelling or haematoxylin staining, with total body length (cm) as the covariate. Finally, a discriminate function analysis was used to determine the accuracy of assigning the acute and chronic stress categories, based on average gland mass, average cortex to medulla ratio, and the percentage of IHC labelling or haematoxylin staining. Data are presented as mean  $\pm$  standard error. All statistical analyses were performed with SPSS for Windows, version 11.5.0, the level of statistical significance being set at  $P < 0.05$ .

## Results

The adrenal glands of 68 Atlantic bottlenose dolphins ranging in age from neonatal to 43 years were examined. Diseases observed and cause of death, age, sex, and sexual maturity status were determined for each animal (Table 1). All adrenal glands appeared grossly normal, without obvious cellular damage, and were arranged in the typical mammalian configuration with an outer cortex and central medulla (Fig. 1). Histologically, these glands displayed the typical cetacean pattern, with a zoned and pseudolobulated cortex, medullary band, and a central medulla with medullary projections. While it was recognized that during any stressful event some immediate changes occur at the cellular level, this study focused on "long-term" structural changes in the adrenal gland associated with chronic stress.

**Table 1**  
**Details of 68 bottlenose dolphins**

<i>Dolphin no.</i>	<i>Sex</i>	<i>Sexual maturity</i>	<i>Age (years)</i>	<i>Type of stress</i>	<i>Disease observed or cause of death</i>
CC162	F	I	2.5	Acute	Massive bacterial infection, infection with invasive protozoa
GA426	F	I	2	Acute	Sepsis
GA539	F	I	NE	Acute	Acute viral infection
GA668	F	I	0.5	Acute	Intraspecific aggression
GA769	F	I	0.1	Acute	Social stranding (probable mother stranded a few days earlier)
GA1000	F	I	2.5	Acute	Intraspecific aggression
GA1198	F	I	NE	Acute	Possible boat strike
PA355	F	I	NE	Acute	Intraspecific aggression
PA409	F	I	4.5	Acute	Net entanglement
PA638	F	I	NE	Acute	Superficial shark bites, dehydration, stress cardiomyopathy and heart failure
PO249	F	I	NE	Acute	Volvulus (twisted intestine several months after capture)
PO353	F	I	NE	Acute	Acute viral infection
SP190	F	I	0.3	Acute	Net entanglement
SP189	F	M	8	Acute	Net entanglement
CC186	M	I	2.5	Acute	Meningitis with meningeal fibrosis and hydrocephalus
CC187	M	I	5.5	Acute	Meningitis
GA460	M	I	NE	Acute	Fungal infection of the brain, trachea, and lymph nodes
GA705	M	I	NE	Acute	Heart failure, shark bites, blood loss, hydrocephalus
GA947	M	I	0.5	Acute	Intraspecific aggression
GA1122	M	I	NE	Acute	Severe meningitis and hydrocephalus
LA038	M	I	2.5	Acute	Net entanglement
PA375	M	I	NE	Acute	Social stranding (suspected separation from mother)
PA381	M	I	4.5	Acute	Boat strike
PA572	M	I	0.5	Acute	Entanglement in a crab pot line and stress cardiomyopathy
PA614	M	I	NE	Acute	Intraspecific aggression
PO372	M	I	NE	Acute	Severe meningoencephalitis with meningeal vasculitis and early hydrocephalus
GA803	M	M	17	Acute	Perforated oesophagus, empyema, massive pleural effusion and right lung collapse
GA1027	M	M	19	Acute	Intestinal obstruction, peritonitis, sepsis
GA1148	M	M	NE	Acute	Possible neck trauma; animal appeared healthy with thick blubber and food in stomach
LA042	M	M	NE	Acute	Acute sepsis with terminal heart failure
PA292	M	M	13	Acute	Empyema caused by catfish spine
GA407	F	I	NE	Chronic	Lymphoma or reactive lymphadenopathy
GA484	F	I	NE	Chronic	Amyloidosis
GA535	F	I	NE	Chronic	Meningitis, arthritis of the atlanto-occipital and humeroscapular joints
GA881	F	I	27	Chronic	Angiomatosis, amyloidosis, intra-atrial thrombus, chronic heart failure, liver congestion
CC110	F	M	15	Chronic	Hepatitis
GA406	F	M	NE	Chronic	Amyloidosis, myocardial injury, and a protozoal infection
GA436	F	M	24	Chronic	Lymphangiomyomatosis
GA466	F	M	NE	Chronic	Stingray spine embedded in chest and chronic disease
GA664	F	M	19	Chronic	Cardiac necrosis and mild hepatitis
GA675	F	M	NE	Chronic	Haemangiomas with lung and lymph node lesions and myocardial degeneration
GA699	F	M	11	Chronic	Septic arthritis of the atlanto-occipital and humeroscapular joints, and amyloidosis
GA775	F	M	13	Chronic	Dissemination of infection from a localized abscess associated with rib fractures
PA229	F	M	NE	Chronic	Old age and chronic disease
PA236	F	M	12	Chronic	Active hepatitis, severe parasitism, pneumonia, and myocardial degeneration
PA361	F	M	NE	Chronic	Post-infarction aneurysm, left ventricular hypertrophy, and vasoproliferative lung disease
PA387	F	M	19	Chronic	Chronic lung disease, hepatitis, brain oedema, protozoal infection, and systemic infection
PO275	F	M	7	Chronic	Protozoan infection and arthritic fusion of the atlanto-occipital and humeroscapular joint
SP153	F	M	19	Chronic	Chronic disease and lung parasitism
SP179	F	M	NE	Chronic	Angiomyomatosis
GA286	M	I	2	Chronic	Parasitic infestation
GA425	M	I	4	Chronic	Inflammation of the liver and acute myocardial degeneration
GA476	M	I	6.5	Chronic	Vessel disease and cervical arthritis
GA1119	M	I	NE	Chronic	Pulmonary angiomatosis and severe meningitis
GA1130	M	I	NE	Chronic	Mild angiomatosis and amyloidosis
LA040	M	I	5.5	Chronic	Net entanglement and disease
PI128	M	I	NE	Chronic	Hydrocephalus and sting ray spine embedded in chest cavity
PO256	M	I	NE	Chronic	Angiomyomatosis, erosion of the right ear bone, and pancreatitis
GA440	M	M	43	Chronic	Septic thrombosis of intrahepatic portal vein and congestive heart failure
GA710	M	M	24	Chronic	Sepsis associated with two <i>Vibrio</i> spp. and extensive degeneration of the myocardium

Table 1 (continued)

Dolphin no.	Sex	Sexual maturity	Age (years)	Type of stress	Disease observed or cause of death
GA740	M	M	13	Chronic	Massive pleural effusion
GA1244	M	M	NE	Chronic	Fishing line in mouth and around goosbeak; animal starved
PA224	M	M	NE	Chronic	Massive parasitic infestation and pneumonia
PA342	M	M	23	Chronic	Pneumonia and impaction of fish in the nares
PA397	M	M	14	Chronic	Massive pleural effusion with extensive fibrin deposition
PA608	M	M	NE	Chronic	Chronically ill, severe parasitism, meningeal thickening, and muscle injury
PO331	M	M	NE	Chronic	Old age and chronic disease
SP321	M	M	NE	Chronic	Angiomas, myocardial scarring, chronic meningitis and hydrocephalus

NE, age not estimated; I, immature; M, mature.

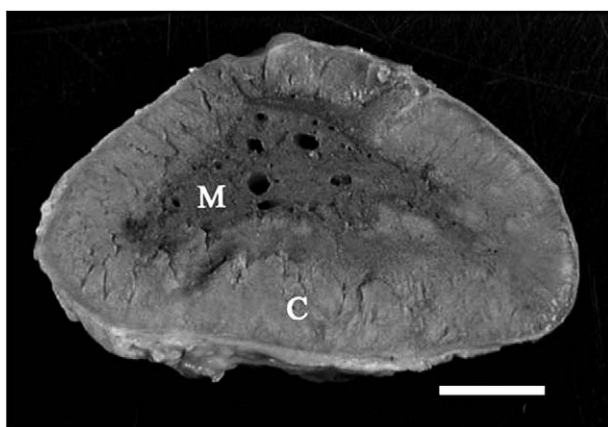


Fig. 1. Cross-section of an Atlantic bottlenose dolphin (*Tursiops truncatus*) adrenal gland. C, cortex; M, medulla. Bar, 0.5 cm.

### Gland Mass

All data sets and measurements were normally distributed (i.e., all  $P$  values were  $> 0.05$ ). Acutely stressed animals had a mean adrenal gland mass of  $4.99 \pm 0.513$  g (range, 1.44–12.2 g) for the right gland and a mean mass of  $5.36 \pm 0.558$  g (range, 1.56–15.5 g) for the left gland. However, chronically stressed animals had a mean gland mass of  $11.07 \pm 0.64$  g (range, 5.38–21 g) for the right gland and a mean mass of  $10.98 \pm 0.53$  g (range, 5.62–18.4 g) for the left gland. No significant differences were found between the right and left adrenal gland mass in either stress category (paired  $t$ -tests:  $t_{27} = -1.772$ ,  $P = 0.088$  for acutely stressed animals and  $t_{35} = -0.439$ ,  $P = 0.664$  for chronically stressed animals). Since there was no apparent difference in mass between the left and right adrenal glands, both masses were averaged together for the remaining analyses to obtain the average gland mass (AGM).

Because organs and glands of cetaceans continue to grow throughout life, with growth slowing after the onset of sexual maturity (Cowan, 1966; Turner *et al.*, 2006), total body length (cm) was used as a covariate to cor-

rect for age-related effects. After accounting for the significant effect of total body length (ANCOVA:  $F_{1,68} = 5.525$ ,  $P = 0.022$ ) on AGM, no significant effect of sexual maturity or sex was found ( $F_{1,68} = 3.749$ ,  $P = 0.058$  and  $F_{1,68} = 0.017$ ,  $P = 0.898$ , respectively). However, type of stress (acute or chronic) had a significant effect (ANCOVA:  $F_{1,68} = 14.521$ ,  $P < 0.001$ ) on AGM. Acutely stressed animals had an AGM of  $5.2 \pm 0.51$  g (range, 1.56–13.20 g), while chronically stressed animals had an AGM of  $11.01 \pm 0.57$  g (range, 5.5–19.7 g) (Fig. 2A).

### Cortex to Medulla Ratios

When comparing the ratio of the cross-sectional areas of the cortex to medulla (CM), no statistical differences were found between 26 pairs (right and left) of adrenal glands (paired  $t$ -test:  $t_{25} = -1.798$ ,  $P = 0.084$ ). Since there were no differences in CM ratio along the central portion of the gland (Clark *et al.*, 2005) or between the right and left CM ratios, these ratios were averaged together for the remaining analyses (average cortex/medulla, ACM). No significant differences were found in ACM ratio by sexual maturity or sex (ANCOVA:  $F_{1,37} = 0.014$ ,  $P = 0.908$  and  $F_{1,37} = 0.08$ ,  $P = 0.779$ , respectively). However, significant differences were found by type of stress (acute *vs* chronic) (ANCOVA:  $F_{1,37} = 5.325$ ,  $P = 0.027$ ) (Fig. 2B). Acutely stressed animals had an ACM ratio of  $1.22 \pm 0.059$  (range, 0.85–1.76) and chronically stressed animals had an ACM ratio of  $1.61 \pm 0.125$  (range, 0.73–2.82). Adrenal glands of acutely stressed animals consisted of 48% cortex, 41% medulla, and 11% “other” (connective tissue, blood vessels, and the gland capsule). Adrenal glands of chronically stressed animals consisted of 53% cortex, 36% medulla, and 11% “other”.

Cortex, medulla, and “other” masses were estimated to determine if there were any differences between acutely and chronically stressed animals. Acutely stressed animals had a mean cortical mass of  $2.36 \pm 0.403$  g (range, 0.68–7.04 g), mean medullary

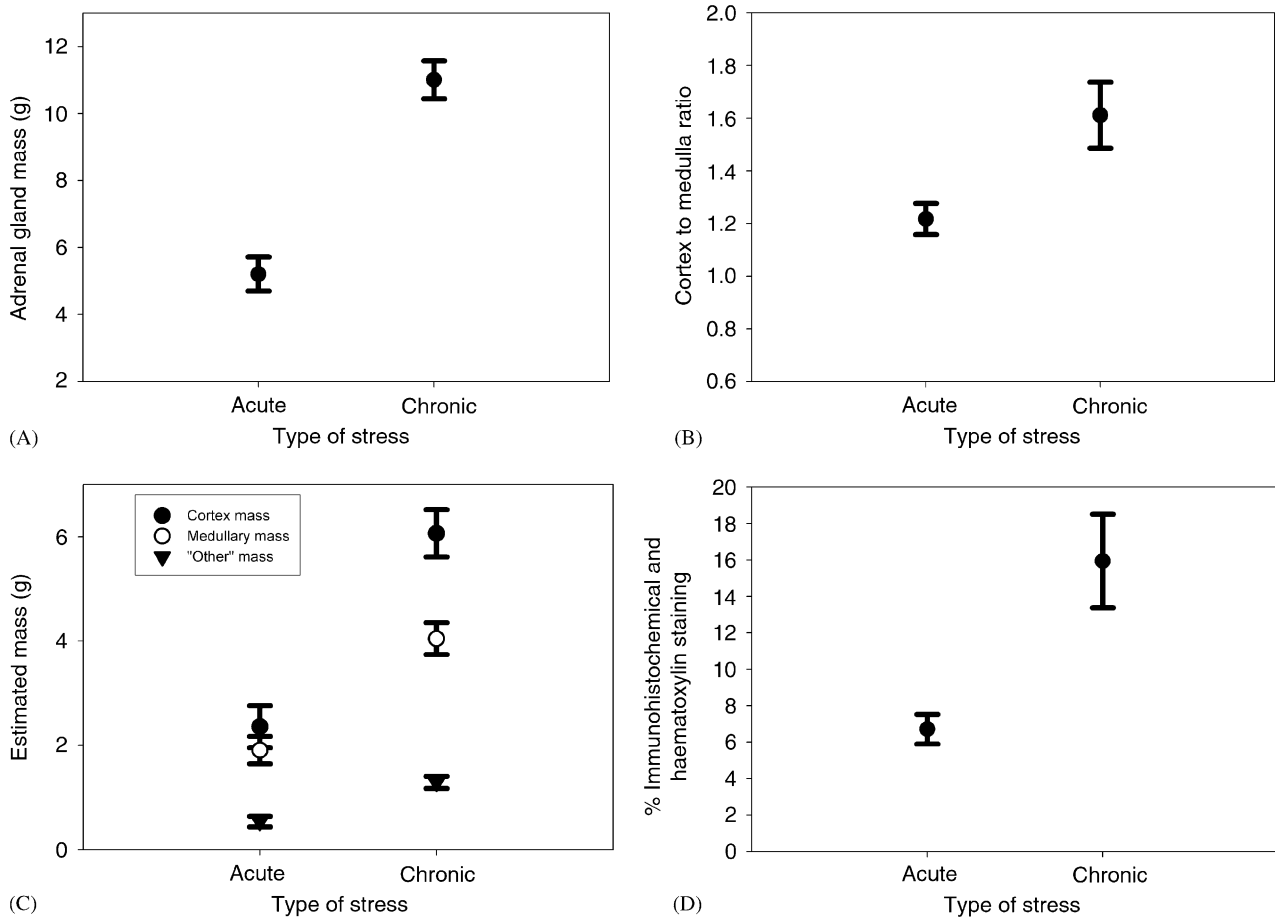


Fig. 2. Comparisons of adrenal glands in acutely stressed and chronically stressed bottlenose dolphins. (A) Mean weights. (B) Mean cortex to medulla ratios. (C) Estimated adrenal cortex, medulla and "other" (see text) masses. (D) Percentage immunohistochemical labelling and haematoxylin staining of the cross-sectional areas. Mean values  $\pm$  standard error are shown.

mass of  $1.9 \pm 0.262$  g (range, 0.61–4.66 g), and mean "other" mass of  $0.54 \pm 0.101$  g (range, 0.13–1.89 g). In contrast, chronically stressed animals had a mean cortical mass of  $6.06 \pm 0.453$  g (range, 3.04–11.33 g), mean medullary mass of  $4.04 \pm 0.305$  g (range, 2.09–9.11 g), and mean "other" mass of  $1.29 \pm 0.116$  g (range, 0.66–2.83 g). Significant differences were found when comparing the cortex, medulla, and "other" masses of acutely stressed animals with those of chronically stressed animals (independent samples *t*-test:  $t_{43} = -5.857$ ,  $P < 0.001$ ,  $t_{43} = -5.073$ ,  $P < 0.001$ , and  $t_{43} = -4.65$ ,  $P < 0.001$ , respectively) (Fig. 2C).

#### Histochemistry

No differences were found when comparing the percentage staining of IHC/HEM by sexual maturity or sex (ANCOVA:  $F_{1,25} = 3.503$ ,  $P = 0.076$  and  $F_{1,25} = 1.204$ ,  $P = 0.285$ , respectively). However, significant differences were found between IHC/HEM staining by type of stress (ANCOVA:  $F_{1,25} = 6.206$ ,  $P = 0.021$ ). Acutely

stressed animals had a mean staining of  $6.7 \pm 0.81\%$  (range, 1.94–10.88%) while chronically stressed animals had a mean staining of  $15.93 \pm 2.57\%$  (range, 4.16–32.09%) (Fig. 2D and Fig. 3A,B).

Discriminate function analysis (DFA) was performed to test for accurate assigning of acute and chronic stress categories based on AGM, ACM ratio, and percentage of IHC/HEM staining. Based on these three factors, there was a significant difference between acutely and chronically stressed animals (Wilks'  $\lambda = 0.292$ ,  $\chi^2 = 22.743$ ,  $P < 0.001$ ). This DFA correctly classified 90.9% of samples to the pre-assigned stress groups with a cross-validation error rate of 13.6%. The DFA was mostly influenced by AGM ( $r = 0.536$ ), followed by percentage IHC/HEM ( $r = 0.48$ ), and ACM ratio ( $r = 0.319$ ).

#### Discussion

The effects of chronic stress on adrenal gland structure and function have been well documented in several

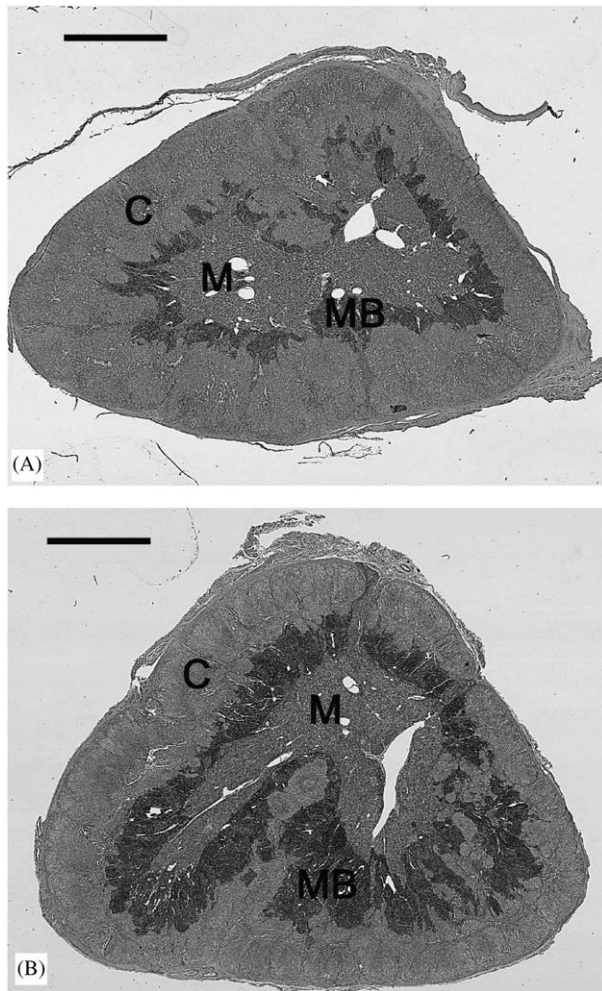


Fig. 3. Cross-sections of adrenal glands of two dolphins. (A) Acutely stressed animal; note the relatively thin medullary band. (B) Chronically stressed animal; note the relatively thick medullary band. C, cortex; M, medulla; MB, medullary band. Overstaining with haematoxylin. Bar, 0.5 cm.

mammalian species (Al-Lami and Farman, 1974; Sakellaris and Vernikos-Danellis, 1975; Anderson and Capen, 1978; Junqueira *et al.*, 1998; Rai *et al.*, 2003). Types of stress in these reports included extended physical immobilization, toxic exposure, psychological stress and disease stress. The effects of chronic stress on cetacean adrenal gland structure and function are not well understood. Initial studies revealed cortical hyperplasia, cortical and medullary nodular hyperplasia, and serous cysts associated with stress related to environmental contamination or chronic illness (Kuiken *et al.*, 1993; Lair *et al.*, 1997).

Histologically, all adrenal glands examined in the present study appeared “normal” (i.e., showing no tumours, cysts, or other lesions) as determined by HE or HPS staining, even in glands from animals deemed to be chronically stressed. There were no statistical differ-

ences in AGM, ACM ratio, or percentage staining of IHC/HEM across different age groups or between sexes. This suggests that *T. truncatus* adrenal glands continue to grow throughout life, the increased growth affecting the cortex, medulla, and epinephrine-producing cells. These findings accord with those of Clark *et al.* (2005) and Turner *et al.* (2006).

In this study, a modified staining technique was used to reveal the medullary band, i.e., the region in which epinephrine-producing cells are located (Clark *et al.*, 2005). Overstaining with haematoxylin (HEM) revealed the highly basophilic chromaffin cells (epinephrine-producing cells) of this region. The medullary band appeared as a prominent band of stained cells, varying in thickness, along the periphery of the medulla (Fig 4A). Immunolabelling of a subset of slides with an antibody against the enzyme PNMT yielded a staining pattern identical with that seen with HEM (compare Figs 4A and 4B). This confirmed that HEM staining emphasized only epinephrine-producing cells. This method of overstaining provided an

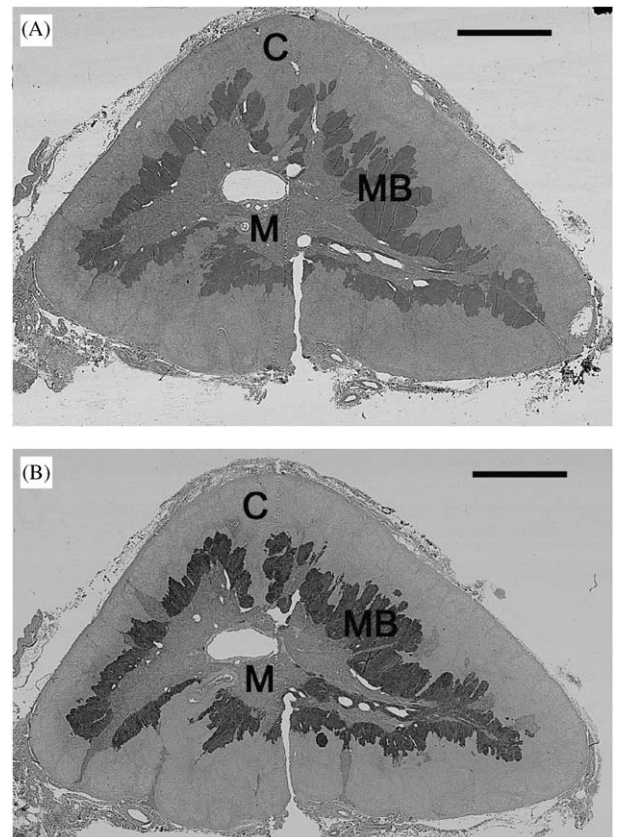


Fig. 4. Cross-section of an adrenal gland from a chronically stressed dolphin, (A) stained with haematoxylin, and (B) immunolabelled for the enzyme phenylethanolamine *N*-methyl transferase (to indicate location of epinephrine-producing cells). Note that the areas stained in A and B are the same. C, cortex; M, medulla; MB, medullary band. Bar, 0.5 cm.

acceptable alternative to immunolabelling of the epinephrine-producing cells.

Adrenal glands of chronically stressed animals were significantly heavier (i.e., had a higher AGM) than those of acutely stressed animals. A similar increase in adrenal gland size and mass was reported in chronically stressed rats (Rai *et al.*, 2003) and diseased harbour porpoises (Kuiken *et al.*, 1993). Taken together, these observations suggest that adrenal gland enlargement may be a common response in cetaceans to chronic stress exerted by long-term diseases or injuries.

The ACM ratio of chronically stressed animals was also significantly higher than that of acutely stressed animals. The former exhibited larger cortices, suggesting cortical hypertrophy or hyperplasia. Supporting this conclusion was the more than two-fold increase in the mass of adrenal cortex, medulla, and "other" tissue. The entire gland increased in mass, but the cortex showed the largest gain ( $\geq 2.5$  fold). Cortical hypertrophy and hyperplasia associated with chronic stress exerted by long-term disease have been reported in the harbour porpoise (Kuiken *et al.*, 1993), beluga whale (Lair *et al.*, 1997), and in domestic animals (Anderson and Capen, 1978). The functional significance of cortical hyperplasia in chronically stressed animals is thought to be related to increased production of adrenocorticotrophic hormones, due to a proliferation of cells in the zona glomerulosa and fasciculata (Junqueira *et al.*, 1998).

IHC labelling and HEM staining indicated that the medullary band increased in thickness in chronically stressed animals, suggesting an increased proportion of epinephrine-producing cells. This possibly results in the production of excessive amounts of epinephrine, a suggestion strengthened by the occurrence of tissue injuries related to the massive release of catecholamines in cetaceans stranded along the Texas Coast (Turnbull and Cowan, 1998) and by studies of the effects of chronic stress in experimental rats (McCarty *et al.*, 1988).

In conclusion, this study indicated that chronic or long-term stress leads to structural changes in the adrenal glands of bottlenose dolphins. Such changes might result in an increase in the capacity to synthesize and store stress hormones. The consequent exaggerated stress response might account for death from heart failure, seen not infrequently in the early stages of attempted rehabilitation.

### Acknowledgments

We thank the co-ordinators and volunteers of the Texas Marine Mammal Stranding Network for their essential assistance, and staff of the University of Texas Medical Branch and University of Alaska Anchorage for

technical and other help. This research was funded by the John H. Prescott Marine Mammal Rescue Assistance Grant Program and the National Sea Grant College Program through the National Oceanic and Atmospheric Administration (NOAA), and the Environmental Protection Agency (EPA) Gulf of Mexico Program. The views expressed herein are those of the authors and do not necessarily reflect the views of NOAA and EPA, or any of their sub-agencies.

### References

- Abdalla, M. A. and Ali, A. M. (1989). Morphometric and histological studies on the adrenal glands of the camel, *Camelus dromedaries*. *Acta Morphologica Neerlandico-Scandinavica*, **26**, 269–281.
- Al-Lami, F. and Farman, N. (1974). Ultrastructural and histochemical study of the adrenal medulla in normal and cold-stressed Syrian hamsters. *Anatomical Record*, **181**, 113–130.
- Anderson, M. P. and Capen, C. C. (1978). The endocrine system. In: *Pathology of Laboratory Animals*, K. Benirschke, F.M. Garner and T.C. Jones, Eds, Springer-Verlag, New York, pp. 423–508.
- Cebelin, M. S. and Hirsch, C. S. (1980). Human stress cardiomyopathy: myocardial lesions in victims of homicidal assaults without internal injuries. *Human Pathology*, **11**, 123–132.
- Clark, L. S., Pfeiffer, D. C. and Cowan, D. F. (2005). Morphology and histology of the Atlantic bottlenose dolphin (*Tursiops truncatus*) adrenal gland with emphasis on the medulla. *Anatomia, Histologia, and Embryologia*, **34**, 132–140.
- Cowan, D. F. (1966). Observations on the pilot whale *Globicephala melaena*: organ weight and growth. *Anatomical Record*, **155**, 623–628.
- Cowan, D.F., (2000). The histopathology of the alarm reaction in dolphins. In: *Proceedings of the American Association of Zoo Veterinarians and the International Association for Aquatic Animal Medicine Conference*, pp. 195–196.
- Cowan, D. F. and Gatalica, Z. (2002). Immunohistochemistry in cetaceans. In: *Molecular and Cell Biology of Marine Mammals*, C.J. Pfeiffer, Ed, Krieger Publishing Company, Malabar, FL, pp. 280–288.
- Dunnill, M.S. (1968). Quantitative methods in histology. In: *Recent Advances in Clinical Pathology*, Series, V. S.C. Dyke, Ed, J and A Churchill, London, pp. 401–416.
- Guyton, A. C. and Hall, J. E. (2000). The autonomic nervous system; and the adrenal medulla. In: *Textbook of Medical Physiology*, 10th Edit., W.B. Saunders Company, Philadelphia, pp. 697–708.
- Hennig, A. (1958). A critical survey of volume and surface measurements in microscopy. In: *Zeiss-Werkzeitschrift*, Number 30, Carl Zeiss, Oberkochen, West Germany, pp. 78–86.
- Hohn, A. A., Scott, M. D., Wells, R. S., Sweeney, J. C. and Irvine, A. B. (1989). Growth layers in teeth from known-age, free-ranging bottlenose dolphins. *Marine Mammal Science*, **5**, 315–342.

- Junqueira, L. C., Carneiro, J. and Kelley, R. O. (1998). *Basic Histology*, 9th Edit., Appleton and Lange, Stanford.
- Kuiken, T., Hofle, U., Bennett, P. M., Allchin, C. R., Kirkwood, J. K., Baker, J. R., Appleby, E. C., Lockyer, C. H., Walton, M. J. and Sheldrick, M. C. (1993). Adrenal cortical hyperplasia, disease, and chlorinated hydrocarbons in the harbour porpoise (*Phocoena phocoena*). *Marine Pollution Bulletin*, **26**, 440–446.
- Kumar, D. and Cowan, D. F. (1994). Cross-reactivity of antibodies to human antigens with tissues of the bottlenose dolphin, *Tursiops truncatus*, using immunoperoxidase techniques. *Marine Mammal Science*, **10**, 188–194.
- Lair, S., Beland, P., DeGuise, S. and Martineau, D. (1997). Adrenal hyperplastic and degenerative changes in beluga whales. *Journal of Wildlife Diseases*, **33**, 430–437.
- McCarty, R., Horwatt, K. and Konarska, M. (1988). Chronic stress and sympathetic-adrenal medullary responsiveness. *Social Science and Medicine*, **26**, 333–341.
- Myrick, A.C., Hohn, A.A., Sloan, P.A., Kimura, M., Stanley, D.D., (1983). Estimating age of spotted and spinner dolphins (*Stenella attenuata* and *Stenella longirostris*) from teeth. National Oceanic and Atmospheric Administration/NMFS Technical Report, SWFSC-30.
- Rai, D., Bhatia, G., Sen, T. and Palit, G. (2003). Comparative study of perturbations of peripheral markers in different stressors in rats. *Canadian Journal of Physiology and Pharmacology*, **81**, 1139–1146.
- Randall, D., Burggren, W. and French, K., (2002). Glands and hormones. In: *Eckert Animal Physiology: Mechanisms and Adaptations*, 5th Edit., Freeman and Company, New York, pp. 301–360.
- Sakellaris, P. C. and Vernikos-Danellis, J. (1975). Increased rate of response of the pituitary-adrenal system in rats adapted to chronic stress. *Endocrinology*, **97**, 597–602.
- Spraker, T. (1993). Stress and capture myopathy in Artiodactylids. In: *Zoo and Wild Animal Medicine*, M.E. Fowler, Ed, W.B. Saunders, Philadelphia, pp. 481–488.
- Turnbull, B. S. and Cowan, D. F. (1998). Myocardial contraction band necrosis in stranded cetaceans. *Journal of Comparative Pathology*, **118**, 317–327.
- Turner, J. P. (1998). *A comparison of the cranial morphology of bottlenose dolphins (Tursiops truncatus) in the Gulf of Mexico*, Masters Thesis. Texas A&M University, College Station, TX.
- Turner, J. P., Clark, L. S., Haubold, E. M., Worthy, G. A. J. and Cowan, D. F. (2006). Organ weights and growth profiles in bottlenose dolphins, *Tursiops truncatus*, from the northwestern Gulf of Mexico. *Journal of Aquatic Mammals*, **32**, 46–57.
- Warnke, R. and Levy, R. (1980). Detection of T and B cell antigens with hybridoma monoclonal antibodies. *Journal of Histochemistry and Cytochemistry*, **28**, 771–776.
- Weibel, A. R. (1963). Principles and methods for the morphometric study of the lung and other organs. *Laboratory Investigation*, **12**, 131–155.

[ Received, December 9th, 2005 ]  
[ Accepted, July 26th, 2006 ]